

Closure:

Hemovac drain:

Bring the drain out through the lateral dorsal side of the foot.

Closure:

The plantar flap is wider than the dorsal flap, so the closure must be done to equally divide and position the two flaps. The extra width is equally spread out over the entire incision – the “divide and conquer” method of closure.

KEY:

Place the 1st suture to oppose the center of the plantar and center of the dorsal flaps. Sew the fascia on the plantar flap to the periosteum that was elevated off the dorsum of the MTs on the dorsal flap.

2nd Suture:

The 2nd deep suture centers the lateral half of the plantar flap to the lateral half of the dorsal flap.

3rd Suture:

The 3rd deep suture further centers the remaining portion of the lateral plantar flap with the remaining portion of the lateral dorsal flap.

4th Suture:

The 4th deep suture begins to center the remaining medial plantar flap to the remaining medial dorsal flap.

5th Suture:

Similarly, the 5th suture centers the central medial plantar to the central medial dorsal.

Continue with subcutaneous closure

“Accordion” skin folding:

Equally spreads out the tissue and helps to best match the larger and wider plantar flap to the smaller dorsal flap.

Nylon skin closure:

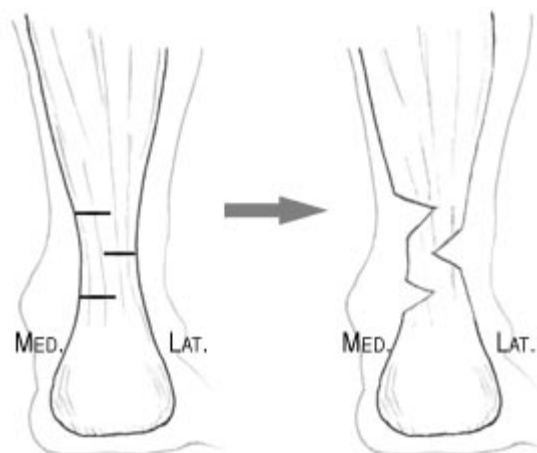
Use 3-0 nylon suture.

Tendon Achilles Lengthening (TAL):

- Check the dorsiflexion of the ankle
- Plan three small incisions to do a Hemi-tendon Transection
- Make 3 cuts in the tendon:

- distal cuts the medial half
- middle cuts the lateral half
- proximal cuts the medial half

- Stretch the step cuts
- Steri-strip closure of the Achilles incisions



©Prosthetics Research Study